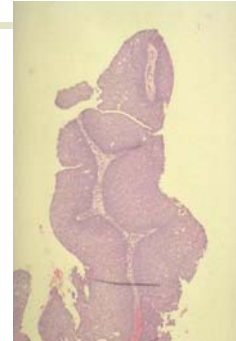


Upper respiratory tract neoplasms

Benign

- Papilloma
 - Occurs in nose, sinuses, larynx (occasionally also in lower airways)
 - Associated with human papilloma virus types 6 and 11
 - Laryngeal lesions commoner in children – can occlude airway

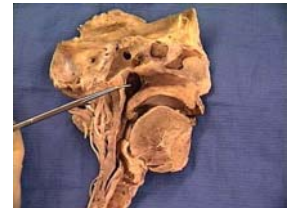

Vocal cord polyps

- Benign non-neoplastic nodules in smokers and those putting strain on vocal cords “singers nodules”

Nasopharyngeal carcinoma

- Great geographical variation in incidence
 - Asia (Far East)
 - Africa
 - Sporadically elsewhere

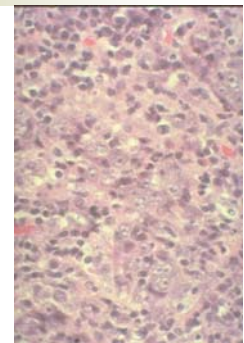


Nasopharyngeal carcinoma

- Strong epidemiological and biological association with Epstein-Barr virus (detectable in tumour)
- Other factors – diet smoking
- Present with neck node enlargement and/or nasal symptoms

Histopathology

- Undifferentiated
 - Differentiated (squamous cell)
- No prognostic difference
Tumour frequently has a dense lymphocytic infiltrate (it is sometimes known as lymphoepithelioma)

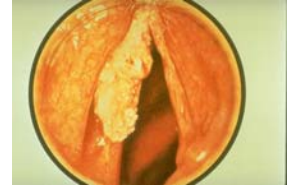


Behaviour

- Spreads to lymph nodes
- Very sensitive to radiotherapy

Laryngeal carcinoma

- Smoking related
- Usually on the vocal cord
- Squamous cell carcinomas
- Preinvasive dysplastic stage is recognised



Laryngeal carcinoma

- Effects by local tissue destruction (loss of voice)
- Neck node metastases

